

Use of laparoscopically mobilized peritoneum in the creation of a neovagina

Claire L. Templeman, M.D.,^a S. Paige Hertweck, M.D.,^a Ronald L. Levine, M.D.,^a and Harry Reich, M.D.^b

School of Medicine, University of Louisville, Louisville, Kentucky; and Columbia Presbyterian Medical Center, College of Physicians and Surgeons, Columbia University, New York, New York

Objective: To present an alternative technique for the creation of a neovagina.

Design: Case study.

Setting: Academic university gynecology clinic.

Patient(s): A patient diagnosed with müllerian agenesis.

Intervention(s): Laparoscopically assisted creation of a neovagina by using peritoneum.

Main Outcome Measure(s): Patient morbidity and satisfactory intercourse.

Result(s): The patient underwent the procedure satisfactorily and was discharged within 24 hours. She had no perioperative or postoperative complications, and she became satisfactorily sexually active.

Conclusion(s): The use of laparoscopically mobilized peritoneum in the creation of a neovagina provided the patient with a functional vagina, allowing satisfactory intercourse. (*Fertil Steril*® 2000;74:589–92. ©2000 by American Society for Reproductive Medicine.)

Key Words: Peritoneum, neovagina, laparoscopy

Many reconstructive techniques for vaginal agenesis have been described, including vaginal dilators, skin-covered molds, sigmoid grafts, and vulval and large muscle flaps. All of these techniques aim to produce a vagina of normal axis, secretory capacity, and length. The most recently reported techniques are laparoscopic modifications of previously described operations, including that of Vecchiatti (1). We report a laparoscopic approach to Davydov's operation that uses peritoneum to line the newly dissected vesicorectal space.

MATERIALS AND METHODS

A 21-year-old patient with vaginal agenesis was referred to the gynecology clinic at the University of Louisville. The patient had initially presented to a gynecologist at 16 years of age with primary amenorrhea. Examination at that time revealed vaginal agenesis with otherwise normal pubertal development. Blood karyotyping revealed a normal female chromosome complement (46XX), and an ultrasonography of the pelvis and kidneys demonstrated bilateral ovaries, a small rudimentary (non-

functioning) uterine horn on the right, and left renal agenesis. Her medical history included ureteric reflux that was corrected with right ureteric reimplantation at 4 years of age. To date, treatment had not been successful with vaginal dilators, and the patient wished to become sexually active. Current examination confirmed the diagnosis of müllerian agenesis and revealed a vaginal dimple approximately 1 cm in depth.

Management options, including structured use of vaginal dilators, McIndoe vaginoplasty, and laparoscopic adaptations of the Vecchiatti and Davydov procedures, were discussed. The patient provided informed consent to undergo the laparoscopic Davydov procedure, therefore negating the requirement for Institutional Review Board approval at our institution.

Under general anesthesia, the patient was placed in the lithotomy position. After catheterization of the bladder, a Verres needle was inserted through a subumbilical incision and a pneumoperitoneum was established. A 10-mm laparoscope was inserted, and two 5-mm ports were placed laterally at the level of the anterior superior iliac spines. The abdomen was care-

Received January 6, 2000;
accepted March 17, 2000.

Reprint requests: Claire Templeman, M.D., Department of Obstetrics and Gynecology, Ambulatory Care Building, University of Louisville, 550 Jackson Street, Louisville, Kentucky 40292 (FAX: 502-852-1911).

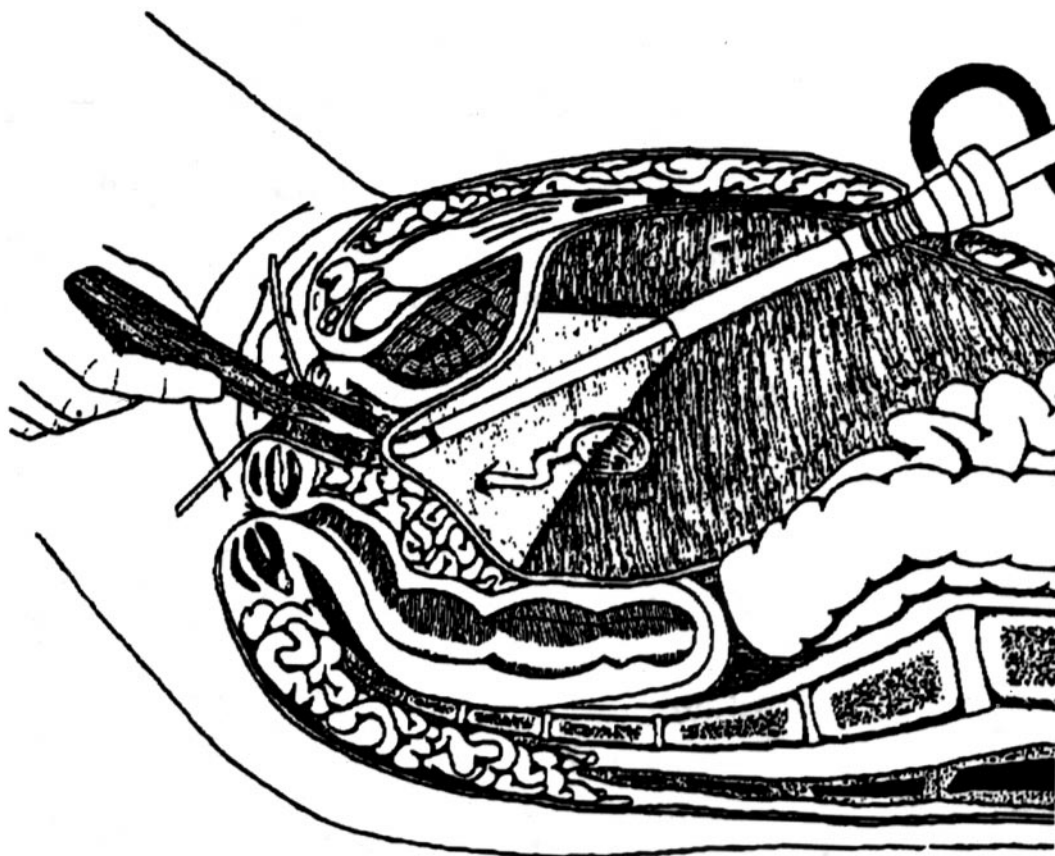
^a Department of Obstetrics and Gynecology, School of Medicine, University of Louisville.

^b Columbia Presbyterian Medical Center, College of Physicians and Surgeons, Columbia University.

0015-0282/00/\$20.00
PII S0015-0282(00)00700-7

FIGURE 1

Laparoscopic mobilization of the peritoneum. Reproduced with permission from Adamyan LV. Laparoscopic management of vaginal aplasia with or without functional noncommunicating rudimentary uterus. In: Arregui ME, Fitzgibbons RJ, Katkhouda N, Mckernan JB, Reich H, eds. Principles of laparoscopic surgery. New York: Springer-Verlag, 1995:646–51.



Templeman. Laparoscopic neovagina. *Fertil Steril* 2000.

fully inspected for adhesions, and the anatomy was found to be consistent with the preoperative assessment.

After labial traction, a 3-cm horizontal incision was made in the introitus at the lower edge of the labia minora. With a finger in the rectum, blunt dissection was performed in the vesicorectal space until the peritoneum was visualized. At this point, an atraumatic probe was placed through the left 5-mm port and directed to an area approximately 5–7 cm behind the rudimentary right uterine horn in the midline, as this was deemed the area of greatest peritoneal mobility (Figure 1).

The probe was directed towards the dissecting finger in the vesicorectal space; once the probe was seen to tent the peritoneum by visualizing from below, the peritoneum was grasped through the newly created neovagina with forceps, incised, and sewn to the introitus with circumferential 0 vicryl sutures (Figure 2). Laparoscopically, the peritoneum covering the bladder, lateral pelvic side walls, sigmoid co-

lon, and uterine remnant was grasped sequentially, sutured using 0 vicryl sutures, and tied as a pursestring. This suture was placed at a level approximately 12 cm from the introitus, creating the vaginal vault and fornices. The rudimentary horn was left in place and was incorporated into the pursestring suture to provide added support to the newly created vaginal vault. At the conclusion of the operation, a Foley catheter was inserted into the bladder and a soft, inflatable stent was placed in the neovagina. Operative time was 90 minutes, and the vagina was approximately 12 cm in length and comfortably admitted two fingers.

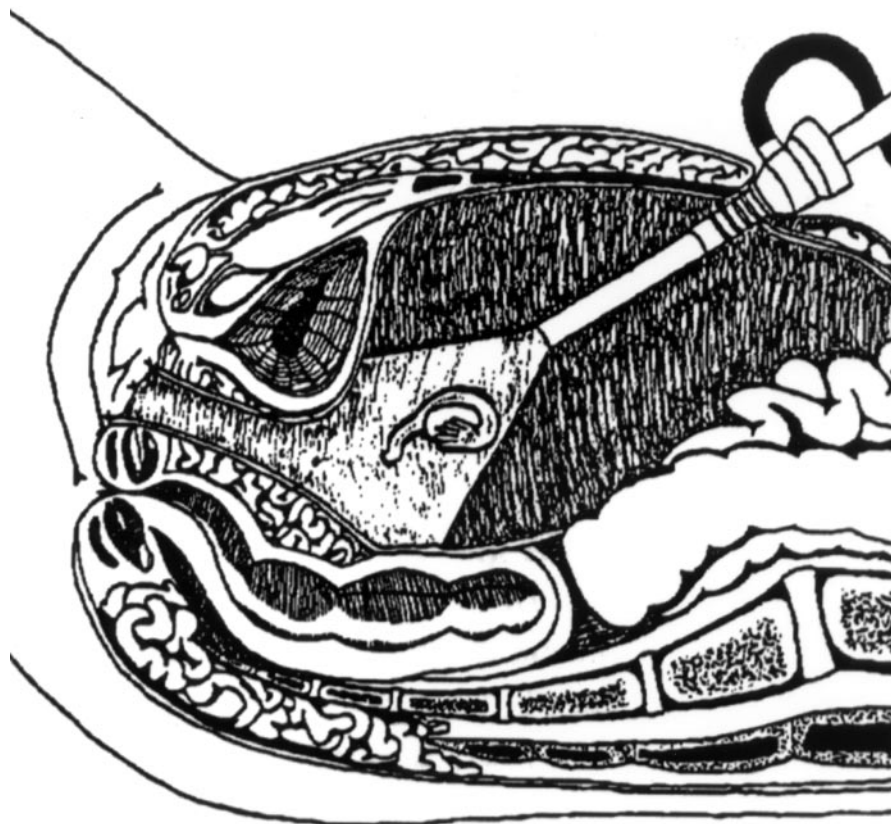
On the day after surgery, after successfully voiding and receiving instruction on vaginal stent insertion and removal, the patient was discharged home.

RESULTS

Pelvic examination 6 days after surgery revealed a neovagina 12 cm in length that accommodated a medium-sized

FIGURE 2

After mobilization, the peritoneum lines the neovagina and is sutured to the vaginal introitus. Reproduced with permission from Adamyan LV. Laparoscopic management of vaginal aplasia with or without functional noncommunicating rudimentary uterus. In: Arregui ME, Fitzgibbons RJ, Katkhouda N, Mckernan JB, Reich H, eds. Principles of laparoscopic surgery. New York: Springer-Verlag, 1995:646–51.



Templeman. Laparoscopic neovagina. *Fertil Steril* 2000.

Graves speculum. The patient had no problems and had kept the vaginal stent in place at all times except during bowel movements. She was asked to continue this procedure until her 6-week postoperative visit, at which time she reported intermittent vaginal spotting and examination showed a healed, moist neovagina 12 cm in length with minor evidence of granulation tissue at the vaginal vault. No further treatment was recommended, and she was instructed to sleep with the vaginal stent in place at night unless intercourse was occurring 2–3 times per week.

Three months after surgery, the patient was intermittently and satisfactorily sexually active and still sleeping with the soft stent in place at night. Examination revealed a vagina 8 cm in depth with resolution of the granulation tissue at the vaginal vault. Because sexual contact was inconsistent and some shrinkage in vaginal length had occurred, the patient was given a rigid dilator and was advised to insert it in the neovagina at night in addition to performing active dilatation

for at least 1 hour a day. At review 6 and 9 months after surgery, the patient was regularly and satisfactorily sexually active without problems. Examination revealed a vagina covered with squamous epithelium accommodating a rigid dilator 8 cm in length and 2 cm in diameter.

DISCUSSION

When used as a lining material for a neovagina, peritoneum is beneficial because it allows development of a vaginal environment with an acidic pH and is replaced by squamous epithelium 5–6 months after surgery (2). Davydov (3) developed a threestage operation involving dissection of the rectovesical space, abdominal mobilization of the peritoneum with creation of the vaginal fornices, and attachment of the peritoneum to the introitus. In Davydov's series of 30 patients (3), all but one woman commenced intercourse within 3 weeks of surgery, and at follow-up (range, 6 months

to 2.5 years), all patients had a vaginal length of 8–11 cm. No woman experienced vaginal dryness; however, 2 noticed a scant bloody discharge that resolved without treatment by 2 months after surgery.

The latest modification of the Davydov operation, described above, uses a laparoscopic approach to peritoneal mobilization. It is of benefit because it allows clear visualization of the anatomy, adequate mobilization of the peritoneum, and creation of the neovaginal fornices under direct vision. In addition, the acknowledged advantages of minimally invasive surgery, such as shorter hospital stay and less postoperative pain, further justify a laparoscopic approach.

In a series of 324 patients with vaginal agenesis (2) who underwent vaginal reconstruction using peritoneum, 27 had laparoscopically assisted surgery and the remainder had surgery completed transvaginally. The laparoscopically assisted procedure resulted in a shorter operating time (52 minutes compared with 98 minutes), a lower intraoperative complication rate (0 compared with 2 enterotomies and 1 cystotomy), and shorter hospital stay (2 days compared with 11 days). Although time to follow-up was shorter in the laparoscopy group (range, 6–24 months compared with 2–11 years), the procedure was similarly successful in both groups, as assessed by vaginal structure (depth, width, scarring) and function (satisfactory intercourse).

Soong et al. (4) described the use of laparoscopically mobilized peritoneum (in a very similar technique to that of Adamyan) to line a neovagina in a cohort of 18 patients. No intraoperative complications occurred, and the most common postoperative problem was the presence of granulation tissue at the vaginal vault (mild in 16 and moderate in 2 patients). Sixteen patients were sexually active after surgery,

of whom 14 reported their experience as satisfactory. The experience of the remaining 2 patients was not detailed. Follow-up ranged from 8–40 months, and no cases of vault prolapse or enterocele were reported.

The type of vaginal stent used after surgery appears to be a matter of surgeon preference; favorable results have been reported with the use of both soft and rigid stents. Adamyan (2) described the use of an antiseptic-soaked tampon inserted into the neovagina after surgery and left in place for 48 hours; sexual activity commenced at 2 weeks. Soong et al. (4) described use of a rigid stent (20-mL syringe covered with Vaseline gauze) inserted after surgery that remained in place for 1 week. This was followed by active use of a rigid dilator for 1 hour four times a day. A soft stent was used in our patient, as this is the usual practice in our unit after vaginal reconstructive surgery.

Our case and those of other investigators demonstrate that the technique we describe is safe and efficient and produces a functional vagina. It is therefore an important option to consider when counseling patients with vaginal agenesis about reconstructive surgery.

References

1. Veronikis DK, McClure GB, Nichols DH. The Vecchietti operation for constructing a neovagina: indications, instrumentation, and techniques. *Obstet Gynecol* 1997;90:301–4.
2. Adamyan LV. Laparoscopic management of vaginal aplasia with or without functional noncommunicating rudimentary uterus. In: Arrequi ME, Fitzgibbons RJ, Katkhouda N, McKernan JB, Reich H, eds. *Principles of laparoscopic surgery*. New York: Springer-Verlag, 1995:646–51.
3. Davydov SN. Colpopoiesis from the peritoneum of the uterorectal space. *Obstet Gynecol (Moscow)*. 1969;12:55–57.
4. Soong YK, Chang FH, Lai YM, Lee CL, Chou HH. Results of modified laparoscopically assisted neovaginoplasty in 18 patients with congenital absence of vagina. *Hum Reprod* 1996;11:200–3.